

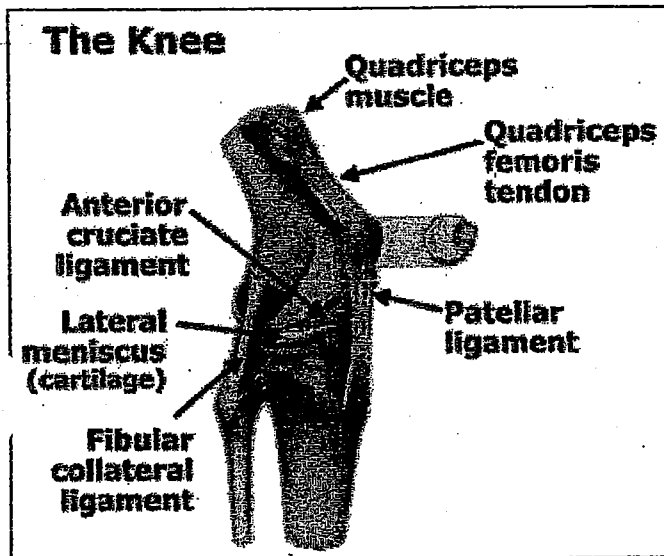
Name: \_\_\_\_\_

Date: \_\_\_\_\_

## Joints – Articulations

**Joints** or articulations exist whenever two or more bones of the body meet. Although structurally the weakest part of the skeleton, joints hold bones together and permit movement of the skeleton.

### Classification of Joints



**Structural classification** depends on whether fibrous tissue, cartilage or a joint cavity separates the bones.

**Functional classification** describes the movement possible at each joint: immovable, slightly moveable or freely moveable.

There are three main types of connective tissue that are important for joint function: **tendons**, **ligaments**, and **cartilage**.

**Tendons** A fibrous connective tissue which connects muscle to bone and muscle to muscle

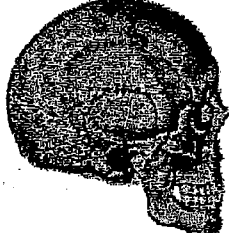
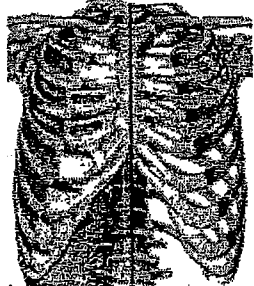
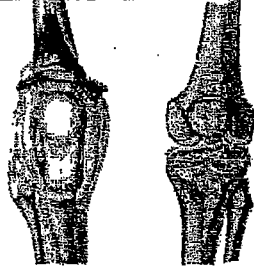
**Cartilage** A 'dense looking' connective tissue which has poor blood supply and lacks nerves. Cartilage falls into three categories:

**Fibrocartilage** between bones as shock absorbers

**Costal cartilage** to connect ribs to the sternum

**Articular cartilage** at the end of articulating bones to reduce friction during movement.

**Ligaments** A band of strong fibrous connective tissue that stabilizes the bones of a joint and connects bone to bone.






Joint Classification and Characteristics			
Structure	Function	Characteristics	Example
<b>Fibrous</b>	Typically fibrous joints are immovable or slightly moveable depending on the location	Held together by fibrous connective tissue. They do not have a joint cavity (e.g. <b>sutures</b> of the skull lock together the irregular shaped bones of the skull).	 <p>Figure 7-18</p>
<b>Cartilagenous</b>	Slightly movable or immovable depending on the location.	The ends of the bones are held together by cartilage and do not have a joint cavity for example, <b>intervertebral</b> joints of the spine (slightly movable), and cartilage which joins <b>ribs</b> to the sternum (immovable).	 <p>Figure 7-19</p>
<b>Synovial</b>	Typically freely movable, but the movement pattern is limited by the structure of the joint	Synovial joints are joints in which the articulating bones (usually long bones) are separated by a cavity filled with fluid (synovial fluid) e.g. knee joint.	 <p>Figure 7-20</p>



## Synovial Joint

Synovial joints allow the greatest amount of movement and regardless of location, display five distinguishing characteristics.

- **Articular cartilage.** Articular cartilage (hyaline) covers the ends of the articulating bones.
- **Articular capsule.** The two bones forming the joint are enclosed by a capsule which has a tough **outer fibrous connective** tissue layer that holds the bones *together and an inner synovial* membrane which secretes synovial fluid.
- **Synovial cavity.** The synovial or joint cavity is the space between the articulating bones within the articular capsule.
- **Synovial fluid.** Synovial fluid fills the joint cavity and assists in lubrication, shock absorption and supply of nourishment. The synovial membrane secretes the fluid.
- **Reinforcing ligaments.** The ligaments join bone to bone and reinforce inside and outside the articular capsule.

**Types of Synovial Joints and Movement Patterns** Although all synovial joints have similar structural components, they do not all have the same movement potential. The movement permitted at each location depends on the structure of the joint and the supporting connective tissue.

<b>Synovial Joint and Movement</b>			
<b>Type</b>	<b>Movement</b>	<b>Location</b>	<b>Example</b>
<b>Gliding.</b> The articular surfaces are flat	Gliding or slipping movements only	Intercarpal joints (between the small bones of the wrist or carpal bones). Figure 7-21	
<b>Hinge.</b> A rounded portion of one bone fits into the depression of another bone to give the appearance of a hinge.	Permits flexion and extension movement only.	The elbow during flexion and extension movements such as the biceps curl. Figure 7-22	
<b>Pivot.</b> The rounded end of one bone extends into the 'sleeve' formed by another bone or a ligament	The rotation of a bone around its long axis is the only movement possible.	The atlas and axis (C1 & 2) during rotation of the head. Figure 7-23	<p><b>Atlas</b></p>  <p><b>Axis</b></p> 
<b>Condyloid.</b> (ellipsoid) The oval surface of one bone fits into the hollow or depression of another bone. Both surfaces are oval.	Permits flexion/extension, abduction/adduction, and circumduction. These are called angular movements.	The wrist joint where the radius articulates with the carpal bones. Figure 7-24	

<p><b>Saddle.</b> Each of the articulating bones have both an elevated and depressed aspects (concave and convex) that give the appearance of a saddle</p>	<p>Permit greater mobility in angular movements but does not allow rotation.</p>	<p>The base of the thumb where the metacarpals articulate with the carpals e.g. 'twiddling your thumbs'. <b>Figure 7-25</b></p>	
<p><b>Ball &amp; Socket</b> (spheroid). The round head of one bone fits into the 'cup like' depression of the other bone.</p>	<p>Permits all types of movements including flexion/extension, abduction/adduction, and rotation.</p>	<p>The shoulder and hip joint are great examples of the high mobility characterized by the ball-and-socket joint. <b>Figure 7-26</b></p>	

## Bursae and Tendon Sheaths

**Bursae** and tendon sheaths are not specifically part of synovial joints, but are commonly associated with them. A Bursa is a bag filled with synovial fluid that lubricates, reduces friction, and cushions. Bursae are found wherever tendons, ligaments, muscles or bones rub together or come in close proximity to each other.

A **tendon sheath** is essentially a tunnel shaped bursa that circles around a tendon to lubricate and protect the tendon from excessive friction or pressure.

## Exercise and Articular Cartilage

Articular cartilage does not have its own blood supply and must rely upon repetitive weight bearing movements to bring in nutrition and remove waste. When the joint is compressed, nutrition is forced into the cartilage and when weight is removed the metabolic wastes flow out and can be removed by the surrounding blood vessels. When synovial fluid is warmed up during exercise, it becomes thinner and absorbed more easily by the cartilage. This increased absorption leads to swelling of the articular cartilage and increased cushioning ability.