

* - Fully flex and extend the knee Joint and observe the movement.

* - Using the scalpel and scissors carefully clean off the joint of any muscle, fat, ligaments and any other loose tissue. As you do so, answer the question below.

3. For each of the following structures, identify the structure on your pig knee, then state which bone it belongs to.

a) Lateral Malleolus (may be cut off): _____

b) Greater Trochanter : _____

c) Medial Malleolus : _____

d) Main Head of a ball and socket joint : _____

e) Lateral Condyles (for both bones) : _____

f) Medial Condyles (for both bones) : _____

- After you have cleaned up the joint, carefully remove some of the synovial capsule membrane (if still present). Look for and identify the following as you open up the joint.

4. Check off each structure that you could locate.

a) Patellar Tendon : _____

b) LCL – Lateral Collateral Ligament: _____

c) MCL – Medial Collateral Ligament : _____

d) ACL – Anterior Cruciate Ligament : _____

e) PCL – Posterior Cruciate Ligament : _____

f) Tibial Lateral Meniscus : _____

g) Tibial Medial Meniscus : _____

h) Femoral Articular Cartilage of the Patellar Surface : _____

5. Using your hands describe the following:

a) The tensile strength of Ligaments : _____

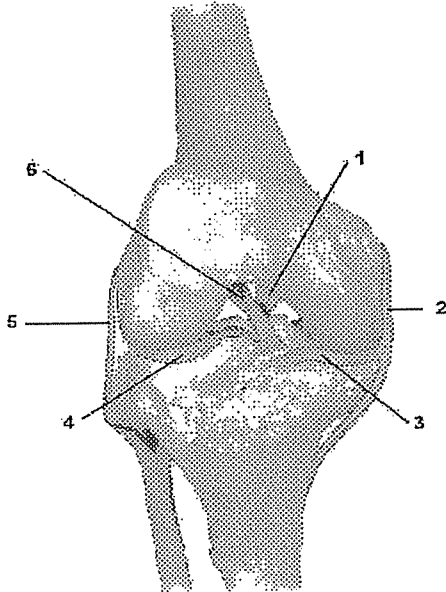
b) The overall texture of the Articular Cartilage: _____

6. Describe the key similarities and differences between the knee of a pig and the knee of a human: _____

**** - Place all of your knee parts and tissues onto paper towel and then discard them into the garbage bag.**
****** - Rinse off all of the dissecting tools and the pan and return them to the proper place. Throw away your gloves and wash your hands and clean off the desk.**

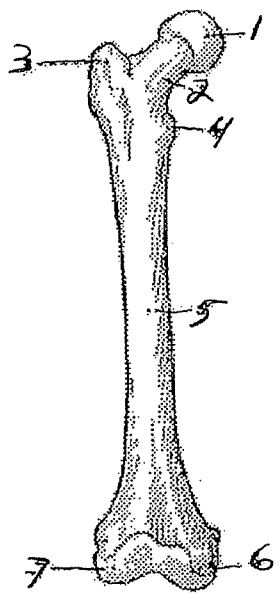
Diagrams:

Label the following diagrams:



- 1. _____
- 2. _____
- 3. _____

- 4. _____
- 5. _____
- 6. _____



- | |
|----------|
| 1. _____ |
| 2. _____ |
| 3. _____ |
| 4. _____ |
| 5. _____ |
| 6. _____ |
| 7. _____ |