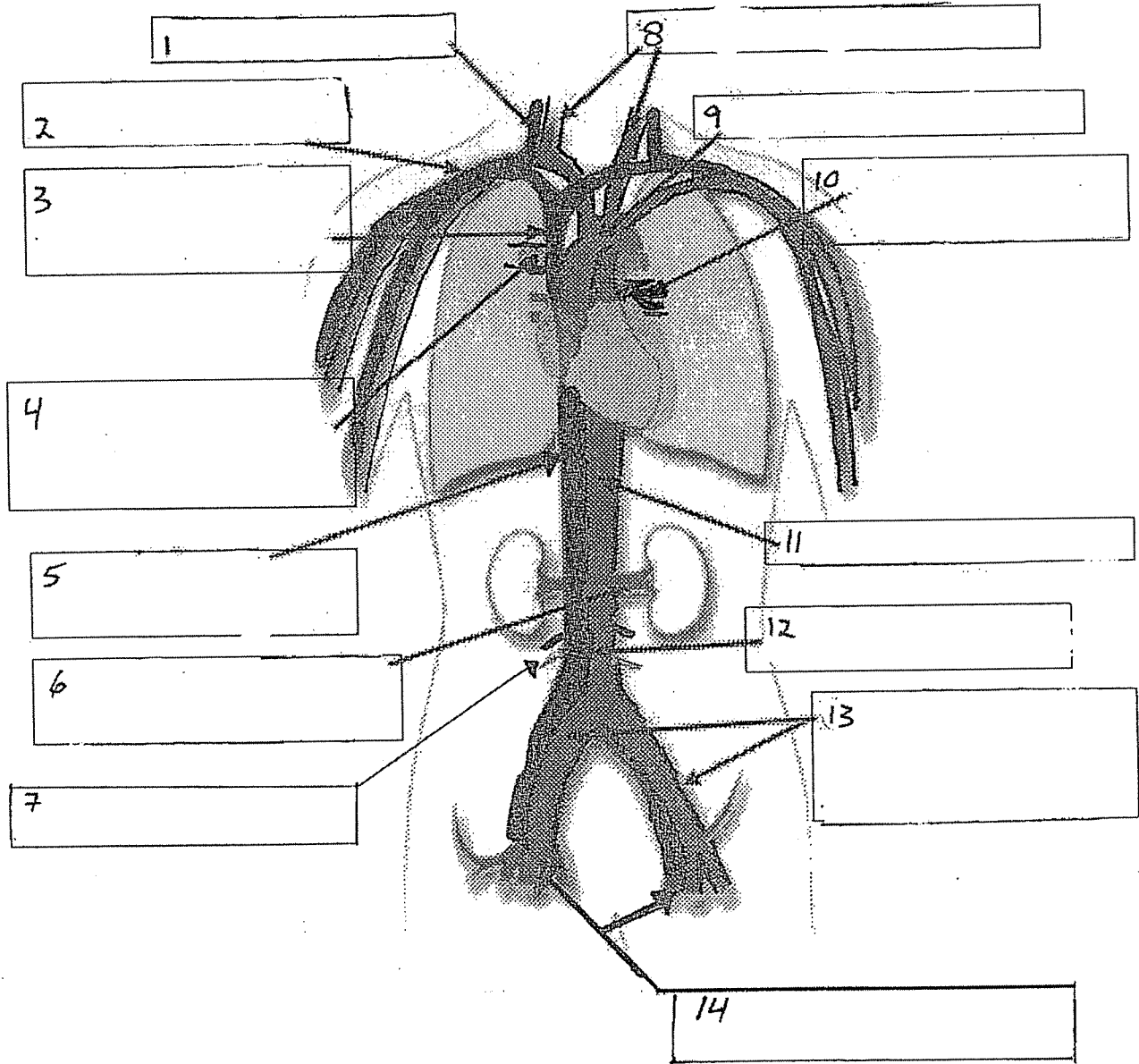


Name: _____

Date: _____

Major Blood Vessels

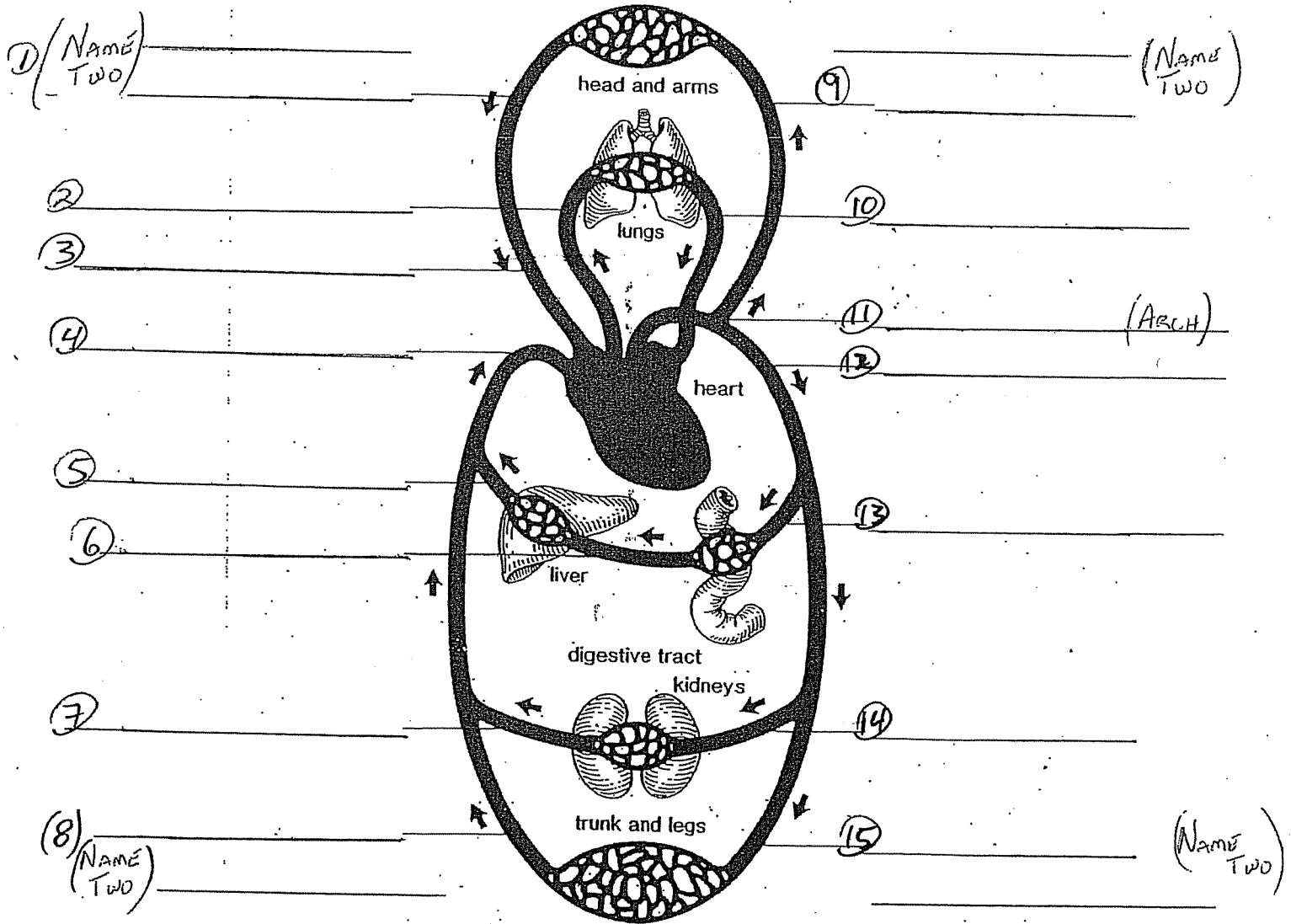


Word Bank – Arteries are lighter gray, while veins are dark gray.

- Common Iliac (vein and artery)
- Inferior (Posterior) Vena Cava
- Aortic Arch
- Jugular Vein
- Carotid Arteries
- Superior (Anterior) Vena Cava
- Renal (artery and vein)
- Mesenteric (vein and artery)
- Pulmonary Artery
- Femoral (vein and artery)
- Abdominal Aorta
- Pulmonary Vein
- Subclavian (vein and artery)
- Thoracic Aorta

* Now Try It Again, But From A Different Point Of View.

MAJOR CIRCULATORY VESSELS



Word Bank -

- Renal Artery
- Common Iliac Vein and Femoral Vein
- Superior (Anterior) Vena Cava
- Hepatic Portal Vein
- Hepatic Vein
- Aortic (Arch)
- Subclavian Arteries and Carotid Arteries
- Mesenteric Artery
- Pulmonary Vein
- Pulmonary Artery
- Renal Vein
- Thoracic Aorta
- Common Iliac Artery and Femoral Artery
- Jugular Vein and Subclavian Vein
- Inferior (Posterior) Vena Cava