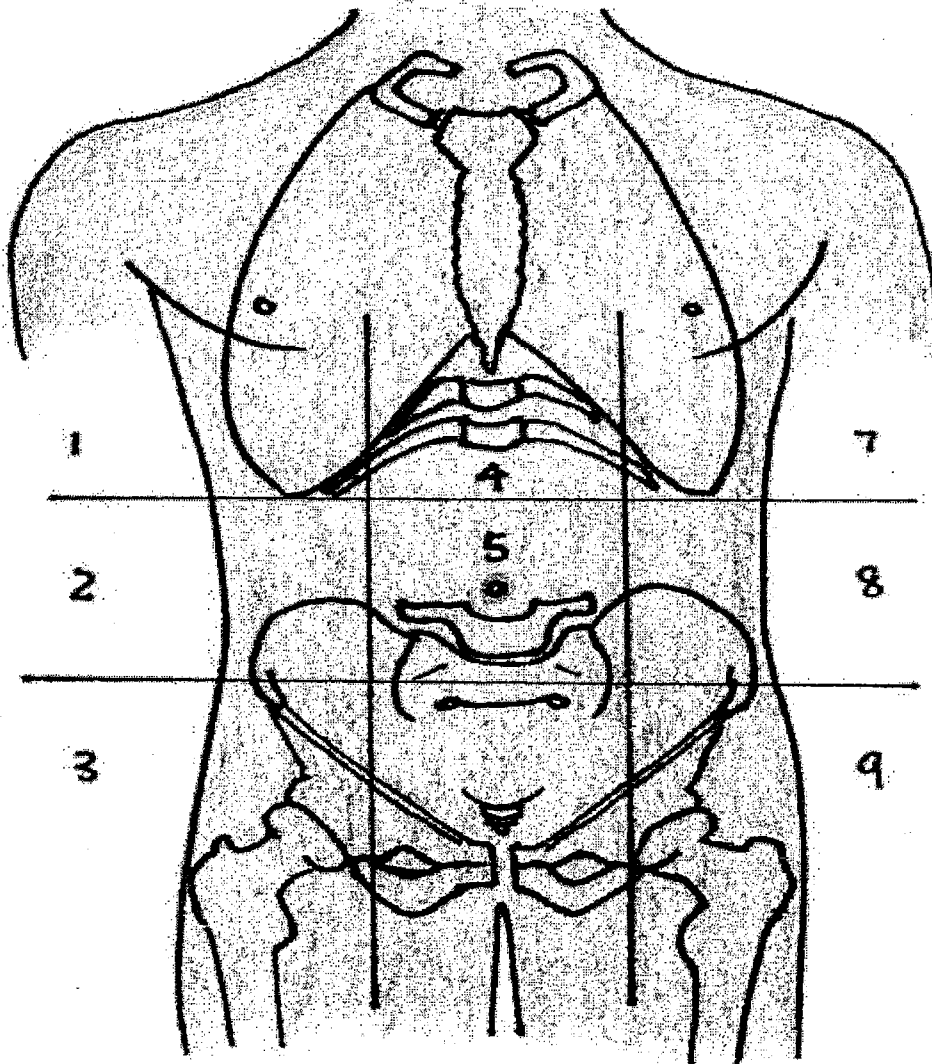


*** Label the 9 main abdominopelvic regions below

ABDOMINOPELVIC REGION



- | | |
|----------|----------|
| 1. _____ | 5. _____ |
| 2. _____ | 6. _____ |
| 3. _____ | 7. _____ |
| 4. _____ | 8. _____ |
| 9. _____ | |

FIGURE 1-8

axial and appendicular divisions of the body. Specific body regions are labeled. Notice how the axial and appendicular regions of the body frame are distinguished by contrasting colors.

